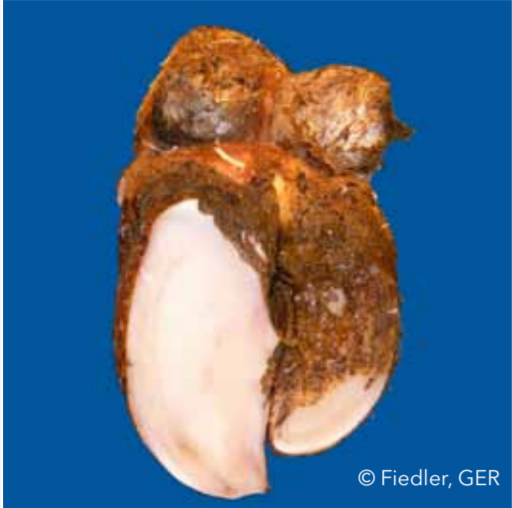

Asymmetric claws (AC)不對稱蹄趾



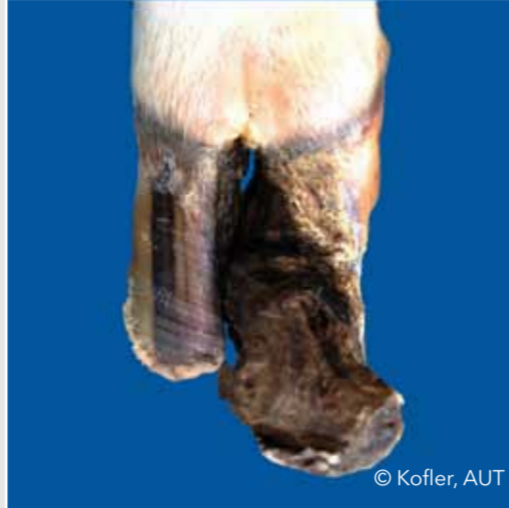外趾與內趾寬度、深度以及長度上明顯不一致，即便是修蹄之後也無法取得平衡。

Concave dorsal wall (CD)蕪蹄



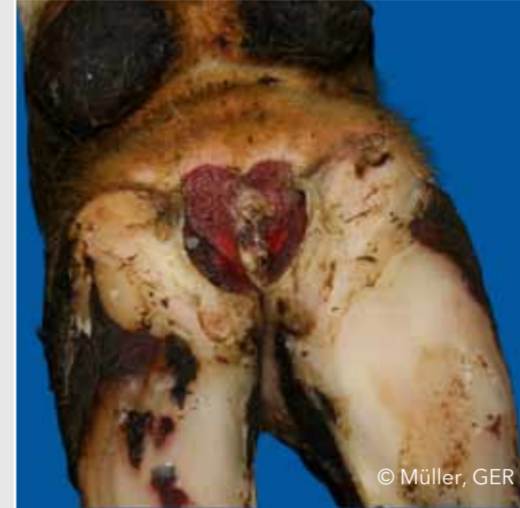趾背凹形，蹄尖壁的角質增厚。

Corkscrew claw (CC)翻卷蹄（螺旋蹄）

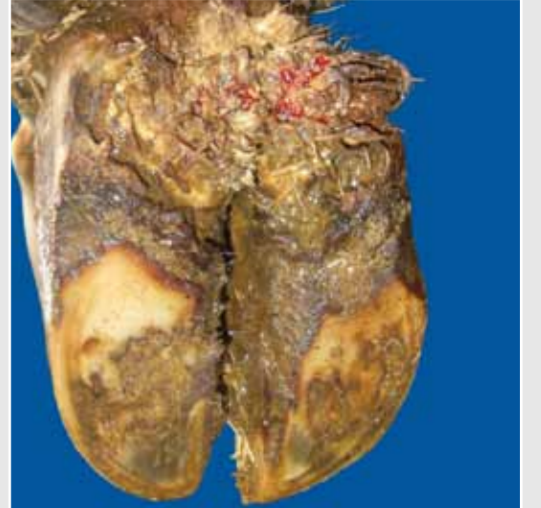

不管是外趾還是內趾均扭曲，趾背邊緣不是一直線。

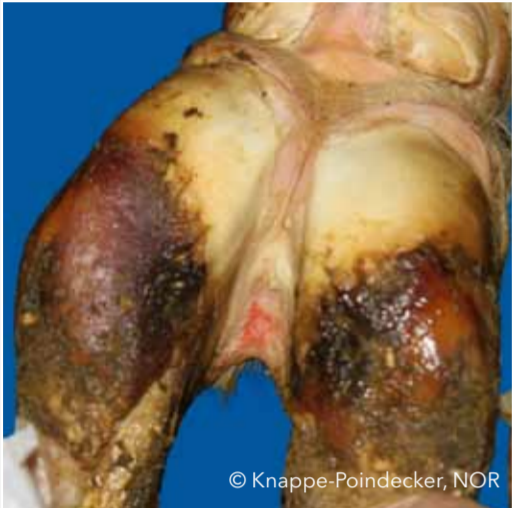Digital dermatitis (DD) 疣狀皮膚炎



由於趾間皮膚感染，造成疼痛性潰瘍或者是角質化與增生。

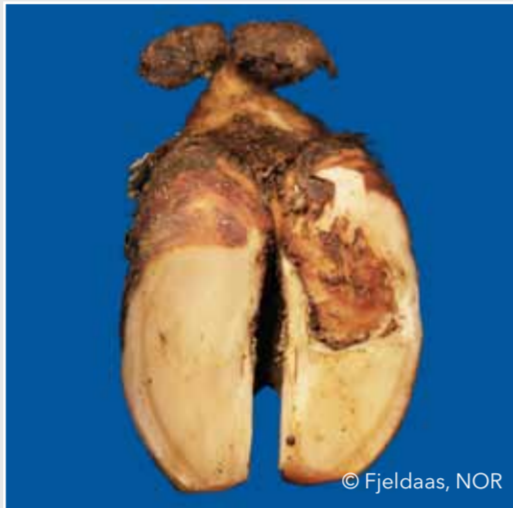

Interdigital/superficial dermatitis (ID)趾間皮膚炎



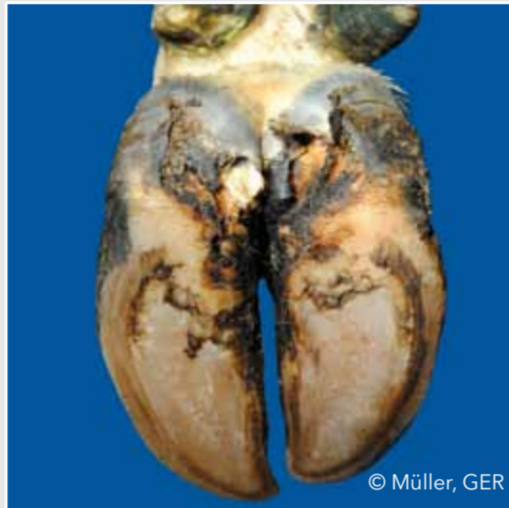
趾間濕疹且發生皮膚炎症，但不是蹄葉炎。

Double sole (DS)雙重蹄底



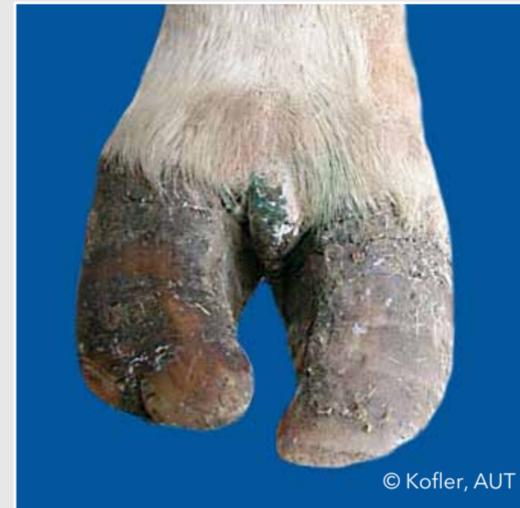蹄底雙層或多層

Heel horn erosion (HHE)蹄跟踵糜爛



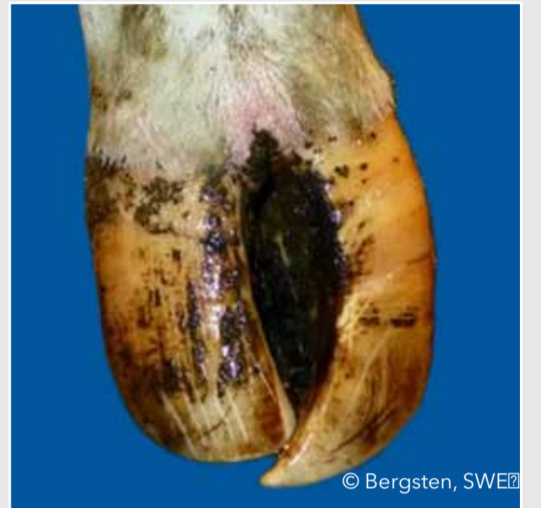蹄底和蹄球踵而糜爛，多形成V字型，很有可能糜爛已擴到真皮層。

Interdigital hyperplasia (IH)趾間皮膚增生



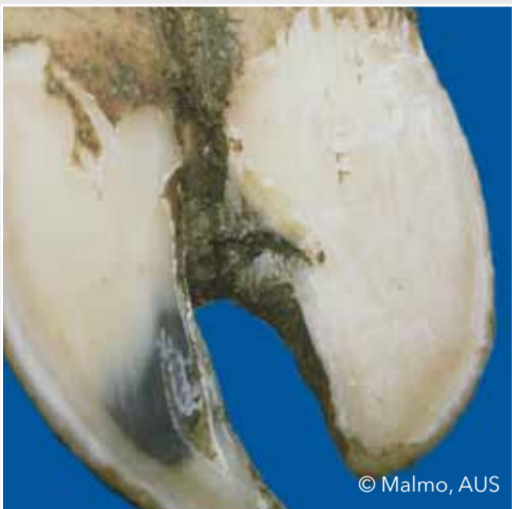趾間生長纖維性組織

Scissor claws (SC)剪刀趾



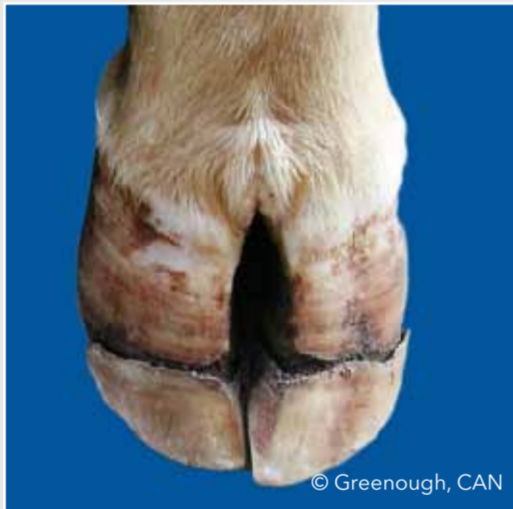趾尖交互生長

Axial horn fissure (HFA)蹄趾間裂



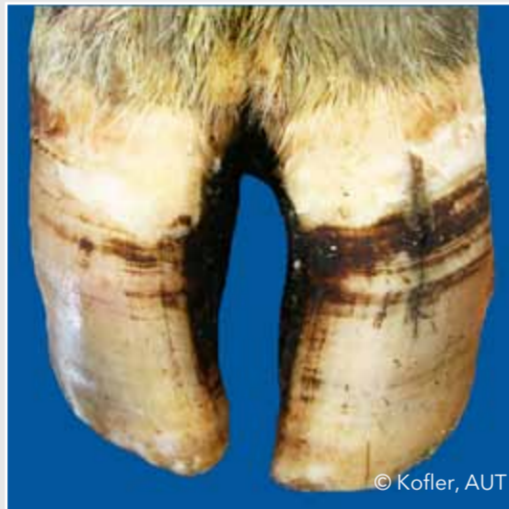內趾壁縱向裂縫

Horizontal horn fissure (HFH)蹄趾壁橫裂



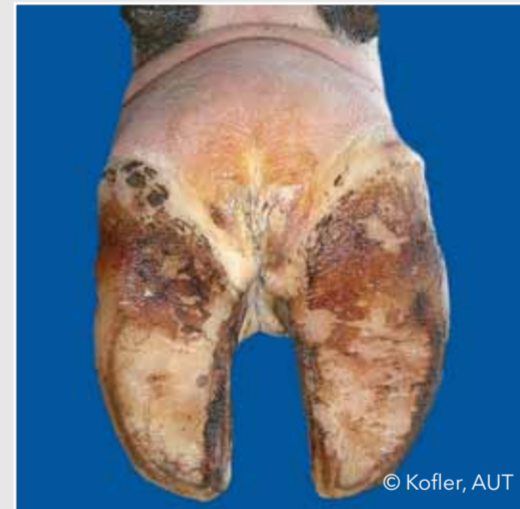蹄趾壁橫裂

Vertical horn fissure (HFV)蹄趾壁縱裂



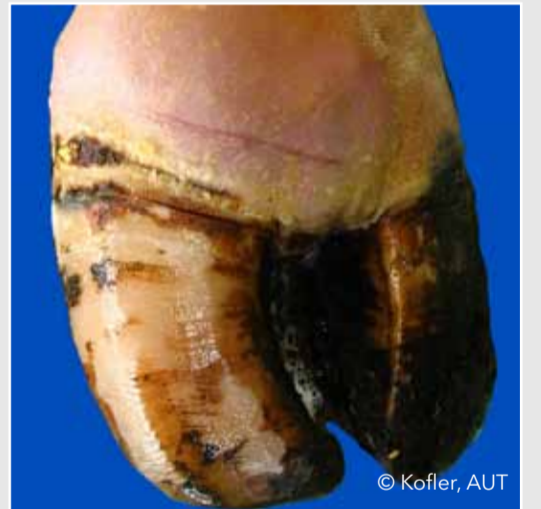外趾壁縱向裂開

Interdigital phlegmon (IP)趾間蜂窩組織炎



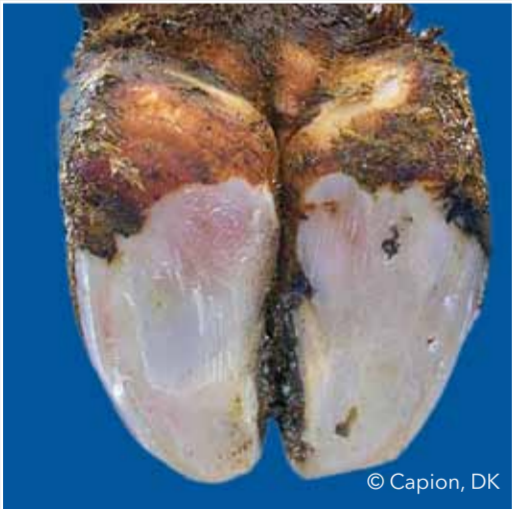
突發性蹄病，帶有難聞氣味、對稱疼痛與跛行。

Swelling of coronet and/or bulb (SW)蹄冠或蹄球腫脹



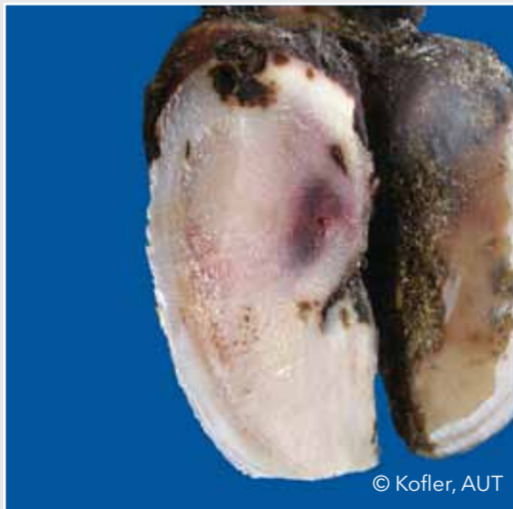由許多因素造成的單邊或雙邊組織腫脹

Sole hemorrhage diffused (SHD)蹄底瀰漫性出血



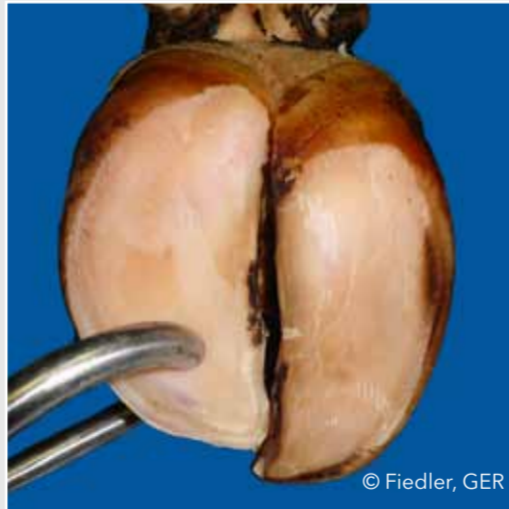Diffused light red to yellowish discoloration

Sole hemorrhage circumscribed (SHC)蹄底局部出血



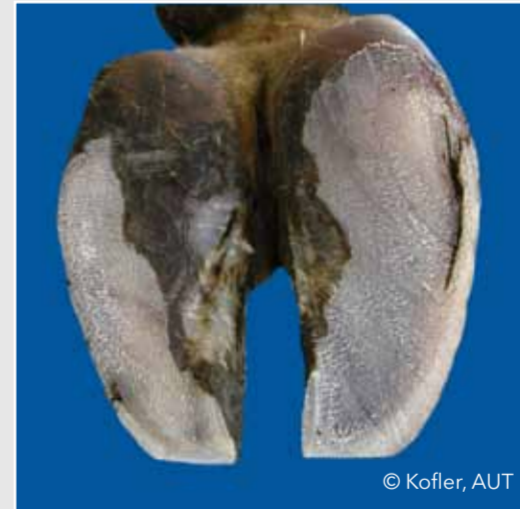Clear differentiation between discolored and normal colored horn

Thin sole (TS) 蹄底變薄



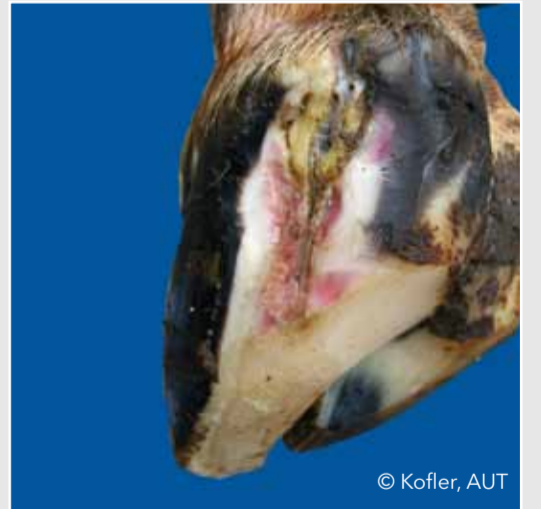
Sole horn yields (feels spongy) when finger pressure is applied

White line fissure (WLF)白線蹄裂



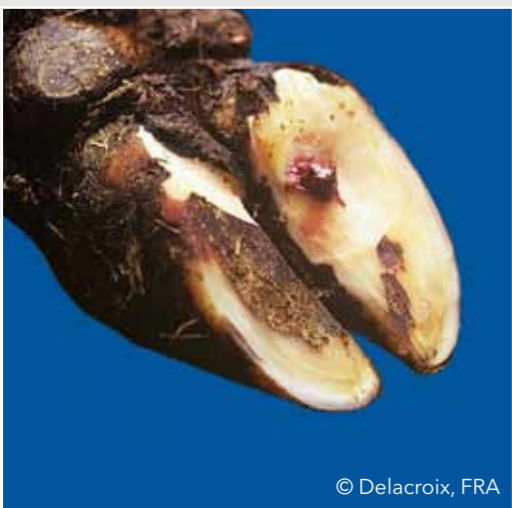Separation of the white line which remains after balancing both soles

White line abscess (WLA)白線膿腫



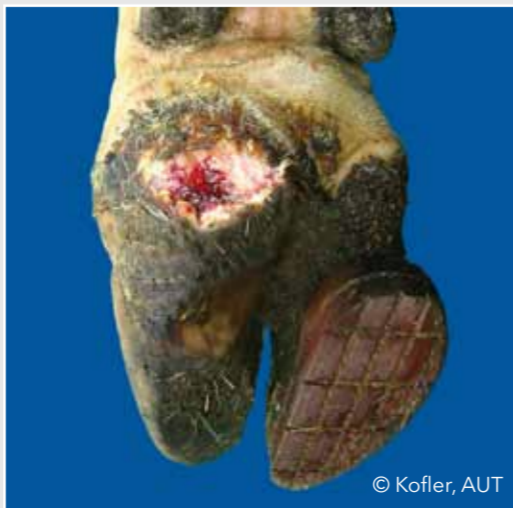Necro-purulent inflammation of the corium

Sole ulcer (SU) 蹄底潰瘍



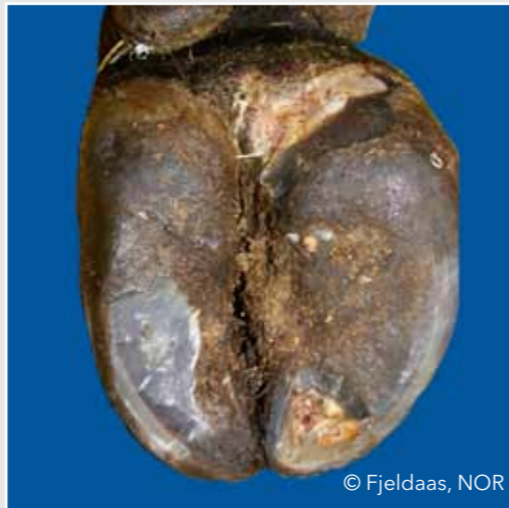Penetration through the sole horn exposing fresh or necrotic corium

Bulb ulcer (BU) 蹄球潰瘍



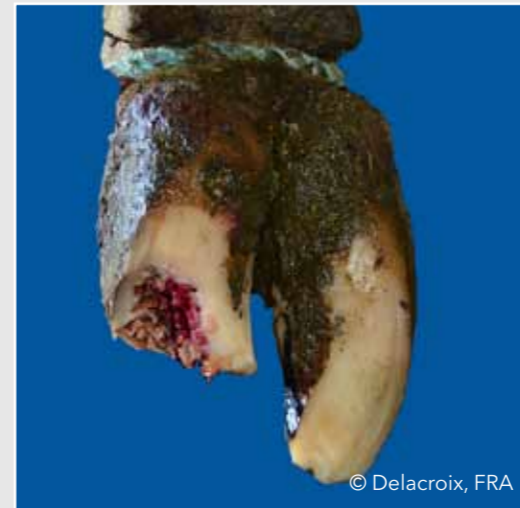Ulcer located at the bulb

Toe ulcer (TU) 蹄尖潰瘍



Ulcer located at the toe

Toe necrosis (TN) 蹄尖壞死



Necrosis of the tip of the toe with involvement of bone tissue