



THE GLOBAL STANDARD
FOR LIVESTOCK DATA

Claw Health Atlas of Section 7 of ICAR Guidelines

Section 7 – Claw Health Atlas

Version March, 2020

Network. Guidelines. Certification.

ICAR CLAW HEALTH ATLAS



2nd revised version



Publishing Information

Title of the Series: ICAR Technical Series

Title of the Issue: ICAR Claw Health Atlas

Editors: ICAR Working Group on Functional Traits (ICAR WGFT) and International Claw Health Experts
(see page 6-7)

Coordination of work: Christa Egger-Danner

Responsible for harmonized descriptions / Citation of the ICAR Claw Health Atlas:

Egger-Danner, C., Nielsen, P., Fiedler, A., Müller, K., Fjeldaas, T., Döpfer, D., Daniel, V., Bergsten, C., Cramer, G., Christen, A.-M., Stock, K. F., Thomas, G., Holzhauer, M., Steiner, A., Clarke, J., Capion, N., Charfeddine, N., Pryce, J.E., Oakes, E., Burgstaller, J., Heringstad, B., Ødegård, C. and J. Kofler

http://www.icar.org/Documents/ICAR_Claw_Health_Atlas.pdf

Layout and design: Franziska Egger, Hollenstein, Austria

Editing of text and pictures: John Cole, USA and Johann Kofler, Austria

Publisher: ICAR, Via Savoia 78, Scala A, Int. 3, 00191, Rome, Italy; Tel: +39 06 85 237 1; Email: icar@icar.org

Copyright by: ICAR, Via Savoia 78, Scala A, Int. 3, 00191, Rome, Italy

ISSN: 92-95014-14-6

ISBN: 92-95014-18

Edition: First edition, June 2015



Table of Contents

Foreword	4
Introduction	5
Authors and Contributors	6
Overview of Foot and Claw Disorders	9
List of Pictures	44



© Pesenhofer, AUT

Foreword

ICAR is an international organisation with the mission of promoting the development and improvement of performance recording and genetic evaluation of farm livestock. Our members are animal recording organisations from around the world and associates who provide services to the animal recording industry. Our eighteen technical Groups, each of which focuses on specific aspects of animal recording or genetic evaluation, carry out much of our work. The work of our Groups generally covers: standards & guidelines, communications, surveys, and innovation. Their output is available from the ICAR website (<http://www.icar.org/>) and is reported at the annual ICAR meetings. ICAR is particularly appreciative of the large amount of work undertaken by the experts who provide their time and knowledge, free of charge, to develop international standards and guidelines for animal recording. As a consequence of this work, the information available from ICAR's members around the world is being used to help farmers make decisions leading to a more efficient animal production sector worldwide.

The ICAR Functional Traits Working Group (ICAR WGFT) is particularly active and has focused on a range of very important traits in dairy cattle including: fertility, udder health, and, most recently, feet and legs. This work is part of ICAR's strategy for helping its members to provide better services to farmers and to facilitate the genetic improvement of farmed livestock, particularly dairy cattle. For the first time we now have an international Atlas and coding system for claw traits in dairy cattle. This represents a major step forward in ensuring the incidence of claw defects affecting animal health, welfare, and productivity can be reduced in the future.

ICAR is focused on continuous improvement and welcomes all feedback on how it can improve its services and in particular the quality of its standards and guidelines.

Hans Wilmink
ICAR President



Introduction

Awareness of the importance of a properly functioning locomotor system to bovine health and welfare has increased around the world. Several countries have recently introduced electronic systems to routinely record foot and claw disorders in dairy cattle and many more countries are developing plans or have committed to begin recording in the near future. This motivated the ICAR working group for functional traits to prioritize foot and claw health and to work with internationally recognized claw experts to develop best practices for data recording. This collaboration is intended to complement existing research on specific aspects of the claws and feet of dairy cattle, focusing solely on the standardization and harmonization of data recording. The harmonized descriptions are the result of fruitful interdisciplinary collaboration among many experts with varying backgrounds (claw health experts, hoof trimmers, bovine practitioners, geneticists), ensuring comprehensive coverage of theoretical and applied needs. It is designed to provide a tool for practitioners and hoof trimmers and presents guidelines for the recording of important conditions affecting the claw health of cattle. Descriptive trait definitions are used to ensure that accurate classifications are made, which will support the collection of comparable and high-quality data within and across countries to support many activities (e.g., genetic evaluation purposes). The authors and contributors to the ICAR Claw Health Atlas hope that the compiled material will support the improved recording of foot and claw disorders and provide a valuable tool for improving the health and welfare of dairy cattle.

The authors and contributors of the ICAR Claw Health Atlas



Authors and Contributors

Austria

Johann Burgstaller, University Clinic for Ruminants,
University of Veterinary Medicine, Vienna
Christa Egger-Danner, ZuchtData EDV-Dienstleistungen
GmbH, Vienna
Johann Kofler, University Clinic for Ruminants, University
of Veterinary Medicine, Vienna
Robert Pesenhofer, Federation of Austrian Hoof Trimmers,
Hitzendorf

Australia

Jakob Malmo, Maffra Veterinary Centre, Maffra
Erika Oakes, Dairy Australia, Southbank, Victoria
Jennie Pryce, Department of Environment and Primary
Industries and La Trobe University, Agribio, Bundoora,
Victoria

Belgium

Nicolas Gengler, Université de Liège - Gembloux Agro-
Bio Tech, Gembloux

Canada

Anne-Marie Christen, Valacta, Québec
Victor Daniel, Vic's Custom Clips est. 1984, Quality
Bovine Hoof Care, Ontario
Paul R. Greenough, Professor Emeritus of Veterinary
Surgery, University of Saskatchewan

Filippo Miglior, Canadian Dairy Network and University of
Guelph, Ontario
Francesca Malchiodi, University of Guelph, Ontario

Denmark

Nynne Capion, Department of Large Animal Sciences,
University of Copenhagen, Copenhagen
Pia Nielsen, SEGES P/S, Aarhus

Germany

Andrea Fiedler, bovine practitioner / Association of
Certified Hoof Trimmers (VgK e.V.), Munich
Kerstin Müller, Veterinary Medicine Faculty,
Freie Universität, Berlin
Kathrin Friederike Stock, vit - Vereinigte
Informationssysteme Tierhaltung w.V., Verden

Finland

Reijo Junni, Environmental Health Office of Central
Ostrobothnia, Kokkola
Elina Paakala, Faba co-op, Vantaa

France

Joël Blanchard, Hoof trimmers training team at CFPPA,
Le Rheu
Marc Delacroix, Veterinarian, member of training team at
CFPPA, Le Rheu



Authors and Contributors

Jean Prodhomme, Hoof trimmers training team at CFPPA,
Le Rheu

Gilles Thomas, Institut de l'Élevage, Paris

Ireland

Keelin O'Driscoll, Teagasc, Moorepark, Cork

The Netherlands

Menno Holzhauser, GD Animal Health, Deventer

Gerben de Jong, CRV, Arnhem

New Zealand

Anna Irwin, DairyNZ, Invercargill

Norway

Terje Fjeldaas, Norwegian University of Life Sciences, Oslo

Björg Heringstad, Norwegian University of Life Sciences /
Geno, Ås

Cecilie Ødegard, Geno, Ås

Maren Knappe-Poindecker, Norwegian University of Life
Sciences, Oslo

Åse Margrethe Sogstad, TINE, Ås

Spain

Noureddine Charfeddine, Conafe, Madrid

Adrián González Sagüés, Anka Hoof Care, Orkoien,
Navarra

Pedro Codesido, Seragro, S. Coop. Galega, A Coruña

Switzerland

Adrian Steiner, University of Bern, Vetsuisse Faculty, Bern

Sweden

Christer Bergsten, Swedish University of Agricultural
Sciences, Alnarp

Karin Ulvshammar, Växa Sverige, Stockholm

United Kingdom

Andrew J Bradley, Quality Milk Management Services Ltd,
Somerset

Jonathan Clarke, SKS Foot trimming Services Ltd,
Seaford, East Sussex

Michael Parkinson, Holstein UK, Herts

Becky Whay, University of Bristol, School of Veterinary
Sciences Langford, Bristol


United States of America

John Cole, Animal Genomics and Improvement
Laboratory, ARS, USDA, Beltsville

Dörte Döpfer, Food Animal Production Medicine, School
of Veterinary Medicine, University of Wisconsin in
Madison, Madison

Gerard Cramer, College of Veterinary Medicine, University of
Minnesota, St. Paul





© Daniel, CAN

Overview of Foot and Claw Disorders

Name	Code	Description	Synonymous Terms	P
Asymmetric claws	AC	Significant difference in width, height and/or length between outer and inner claw which cannot be balanced by trimming		12
Concave dorsal wall	CD	Concave shape of the dorsal wall		13
Corkscrew claws	CC	Any torsion of either the outer or inner claw. The dorsal edge of the wall deviates from a straight line		14
Digital dermatitis	DD	Infection of the digital and/or interdigital skin with erosion, mostly painful ulcerations and/or chronic hyperkeratosis/proliferation	Mortellaro disease, Strawberry disease	15
Interdigital/ superficial dermatitis	ID	All kind of mild dermatitis around the claws, that is not classified as digital dermatitis		18
Double sole	DS	Two or more layers of under-run sole horn	Underrun sole	19
Heel horn erosion	HHE	Erosion of the bulbs, in severe cases typically V-shaped, possibly extending to the corium	Slurry heel, Erosio ungulae	21
Horn fissure	HF	Crack in the claw wall		
Axial horn fissure	HFA	Vertical (longitudinal) crack in the inner claw wall		23

Overview of Foot and Claw Disorders

Name	Code	Description	Synonymous Terms	P
Horizontal horn fissure	HFH	Horizontal crack in the claw wall		24
Vertical horn fissure	HFV	Vertical (longitudinal) crack in the outer or dorsal claw wall		25
Interdigital hyperplasia	IH	Interdigital growth of fibrous tissue	Corns, Tyloma, Interdigital fibroma	26
Interdigital phlegmon	IP	Symmetric painful swelling of the foot commonly accompanied with odorous smell with sudden onset of lameness	Foot rot, Foul in the foot, Interdigital necrobacillosis	28
Scissor claws	SC	Tip of toes crossing each other		30
Sole hemorrhage	SH	Diffused and/or circumscribed red or yellow discoloration of the sole and/or white line	Sole bruising	
Sole hemorrhage diffused form	SHD	Diffused light red to yellowish discoloration		31
Sole hemorrhage circumscribed form	SHC	Clear differentiation between discolored and normal colored horn		32

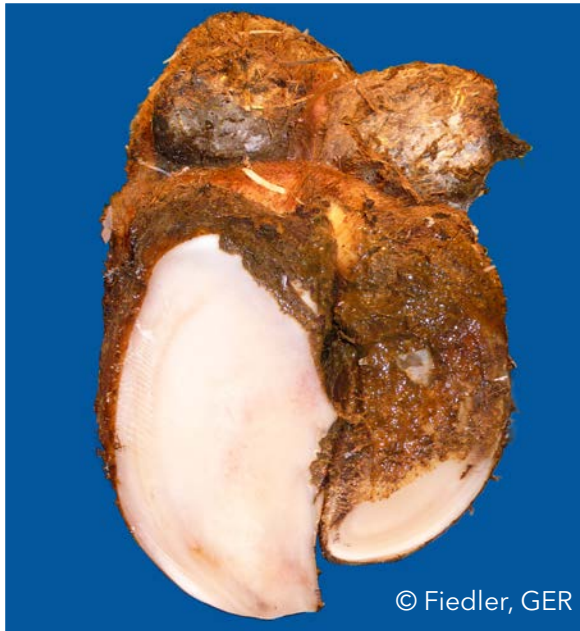

Overview of Foot and Claw Disorders

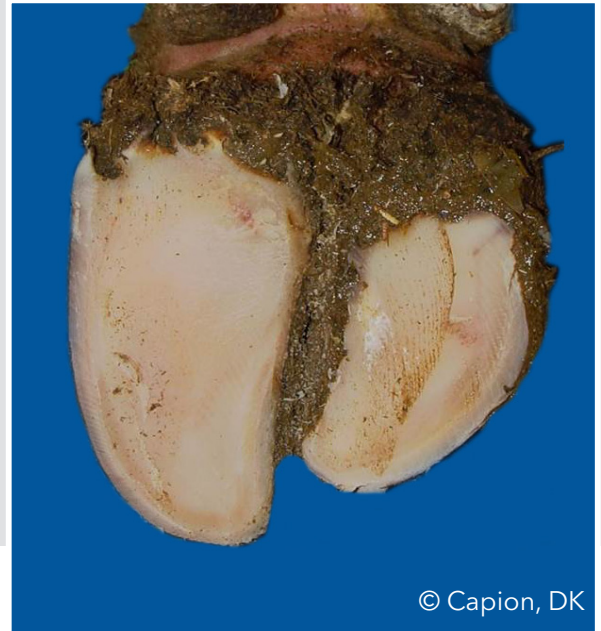Name	Code	Description	Synonymous Terms	P
Swelling of coronet and/or bulb	SW	Uni- or bilateral swelling of tissue above horn capsule, which may be caused by different conditions		33
Ulcer	U	Ulceration of the sole area specified according to localization (zones) such as bulb ulcer, sole ulcer, toe ulcer, toe necrosis		
Sole ulcer	SU	Penetration through the sole horn exposing fresh or necrotic corium		35
Bulb ulcer	BU	Ulcer located at the bulb	Heel ulcer	36
Toe ulcer	TU	Ulcer located at the toe		37
Toe necrosis	TN	Necrosis of the tip of the toe with involvement of bone tissue		38
Thin sole	TS	Sole horn yields (feels spongy) when finger pressure is applied		40
White line disease	WL	Separation of the white line with or without purulent exudation		
White line fissure	WLF	Separation of the white line which remains after balancing both soles		41
White line abscess	WLA	Necro-purulent inflammation of the corium		42

Asymmetric claws (AC)

Significant difference in width, height and/or length between outer and inner claw which cannot be balanced by trimming



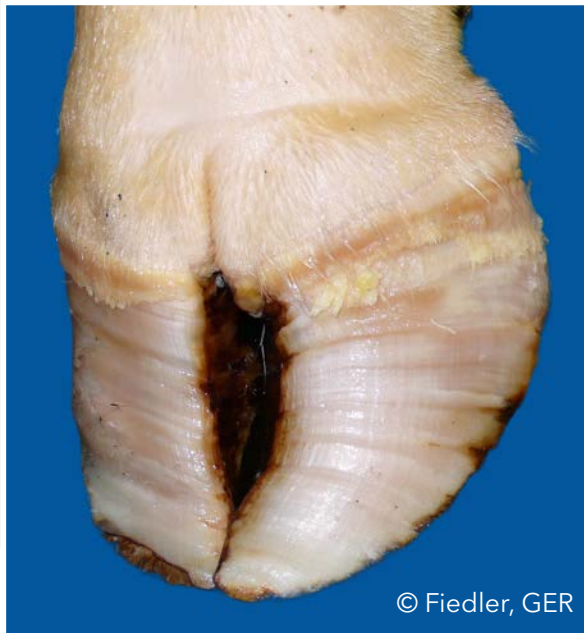© Fiedler, GER



© Capion, DK

Concave dorsal wall (CD)

Concave shape of the dorsal wall



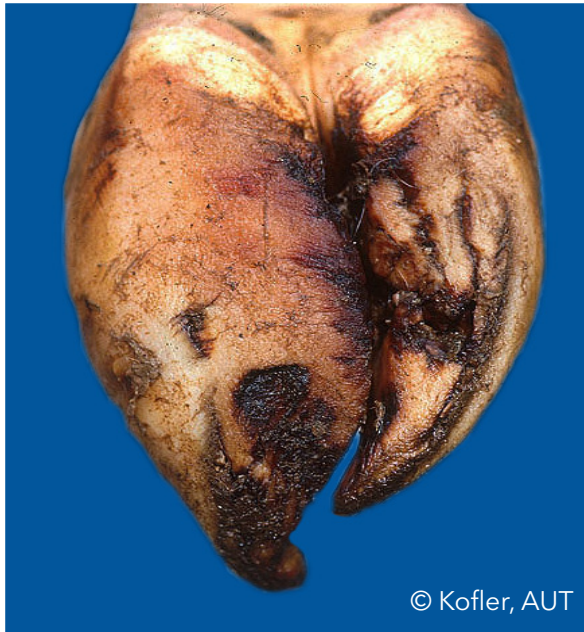© Fiedler, GER



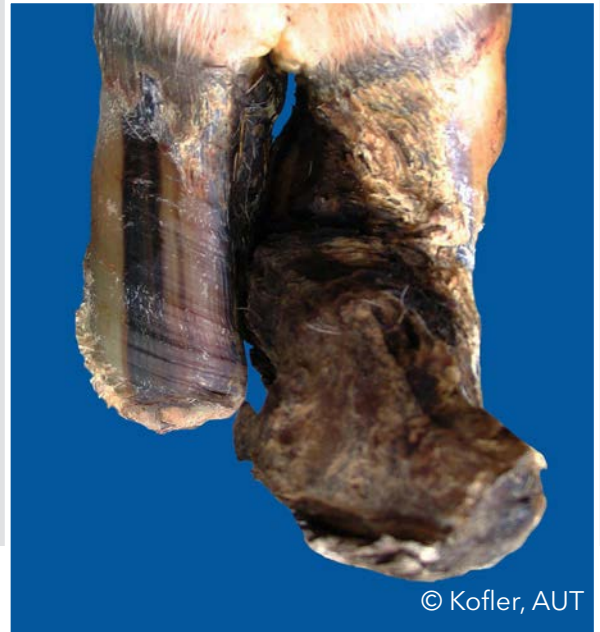© Thomas, FRA

Corkscrew claw (CC)

Any torsion of either the outer or inner claw. The dorsal edge of the wall deviates from a straight line



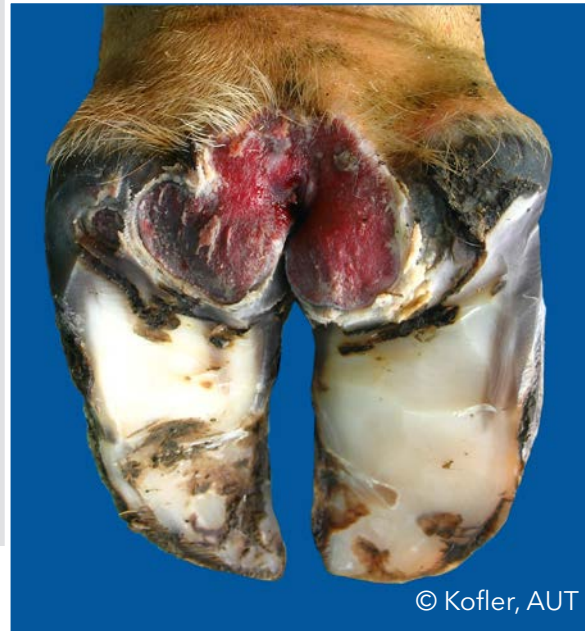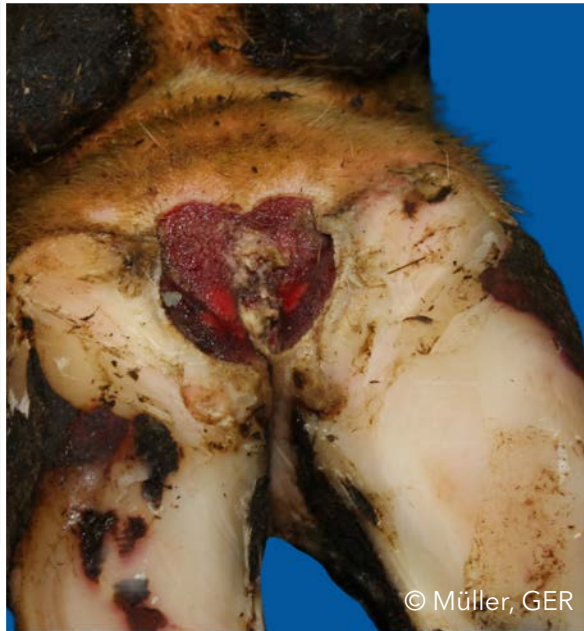© Kofler, AUT



© Kofler, AUT

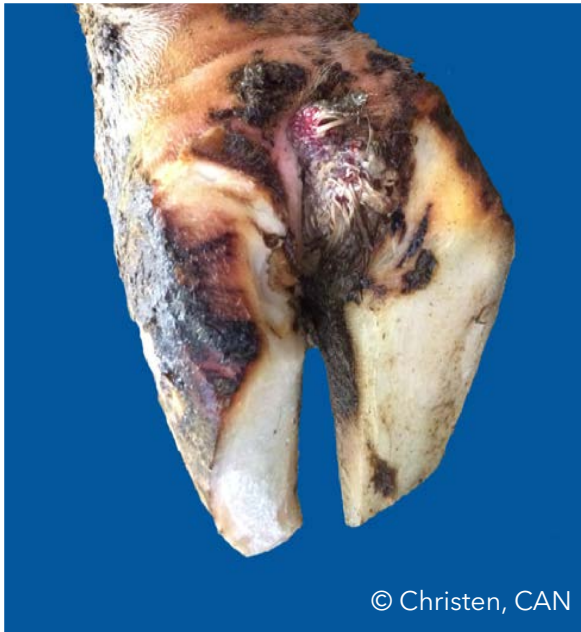Digital dermatitis (DD)

Infection of the digital and/or interdigital skin with erosion, mostly painful ulcerations and/or chronic hyperkeratosis/proliferation

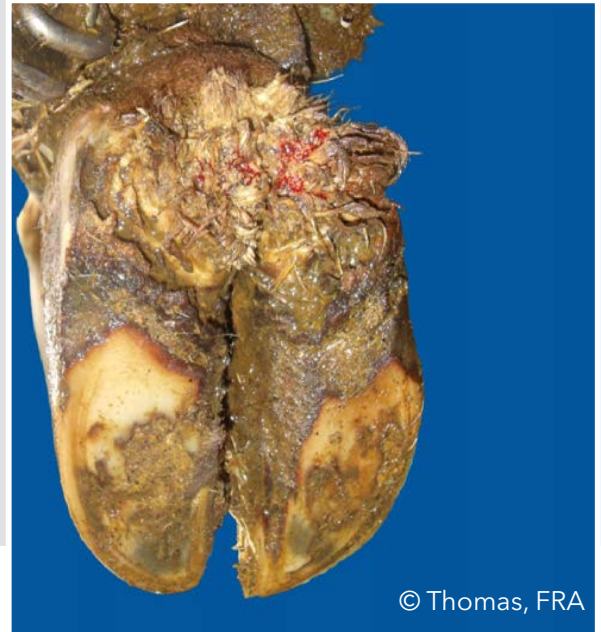


Digital dermatitis (DD)

Infection of the digital and/or interdigital skin with erosion, mostly painful ulcerations and/or chronic hyperkeratosis/proliferation



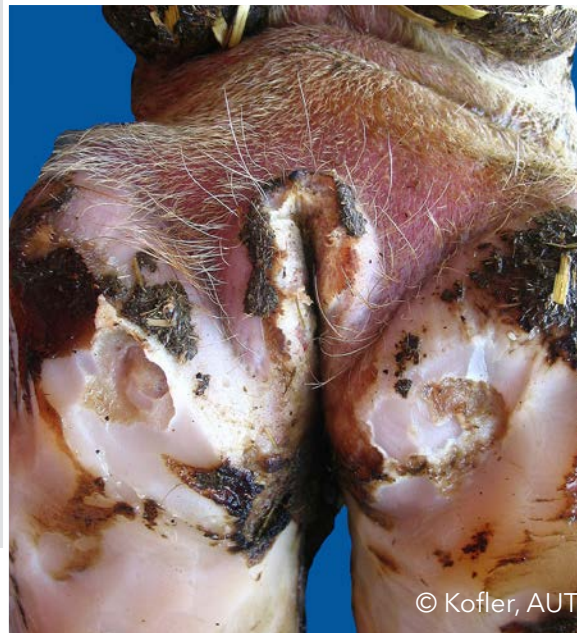© Christen, CAN



© Thomas, FRA

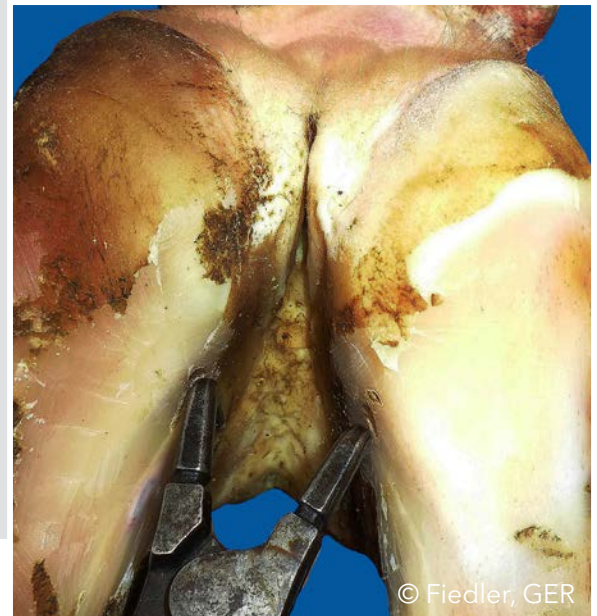
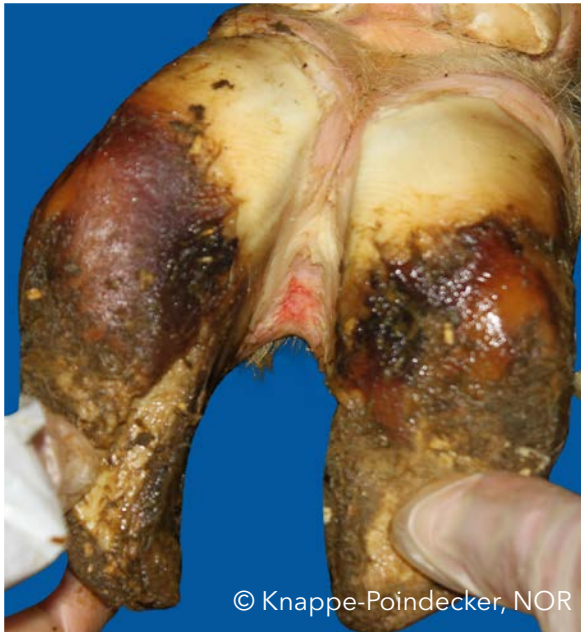Digital dermatitis (DD)

Infection of the digital and/or interdigital skin with erosion, mostly painful ulcerations and/or chronic hyperkeratosis/proliferation



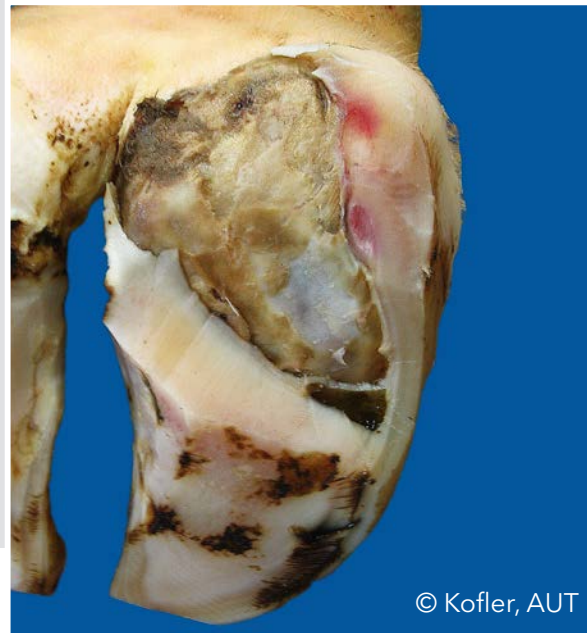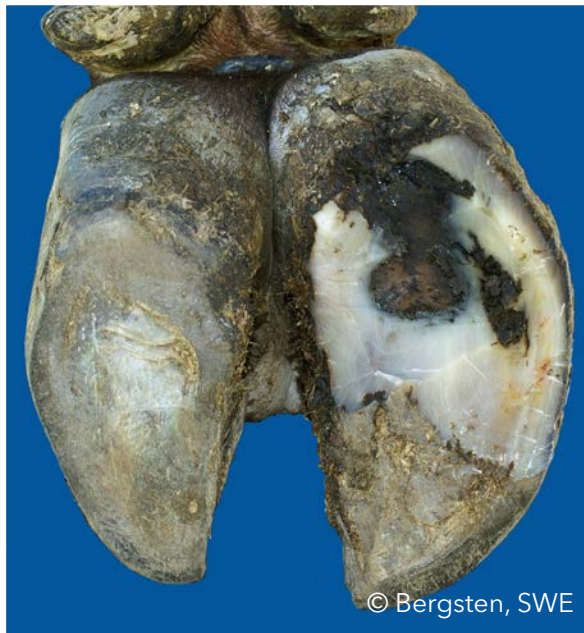Interdigital/ superficial dermatitis (ID)

All kind of mild dermatitis around the claws, that is not classified as digital dermatitis



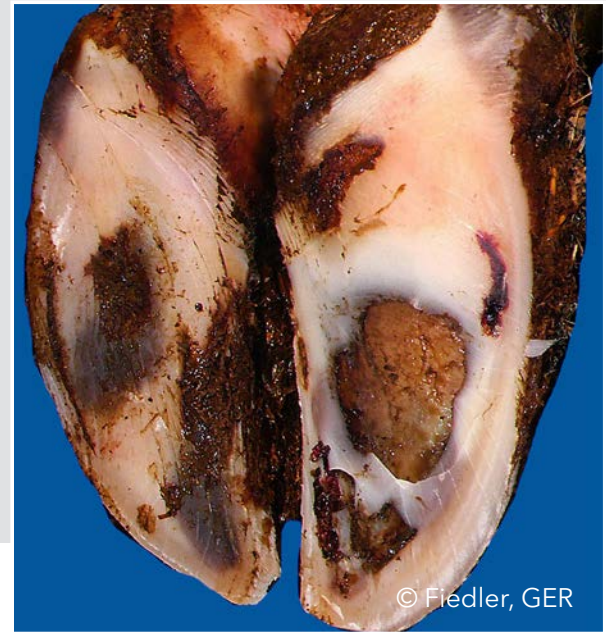
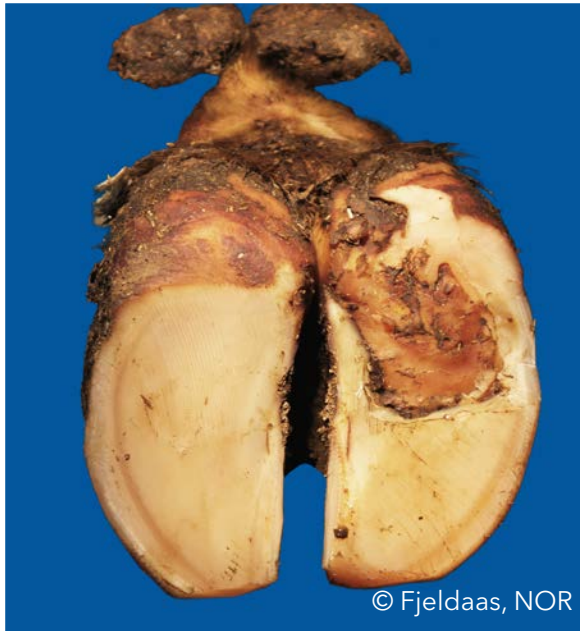
Double sole (DS)

Two or more layers of under-run sole horn



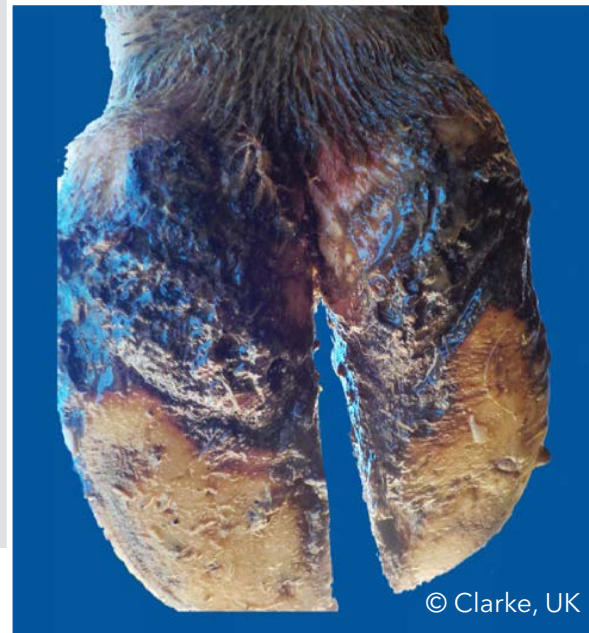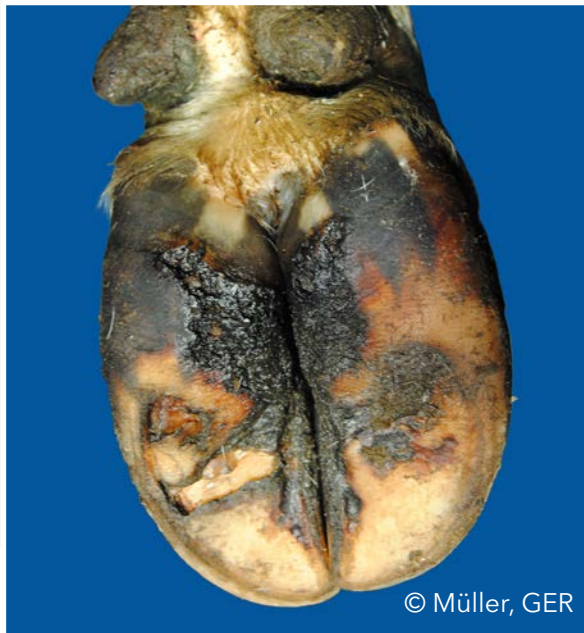Double sole (DS)

Two or more layers of under-run sole horn



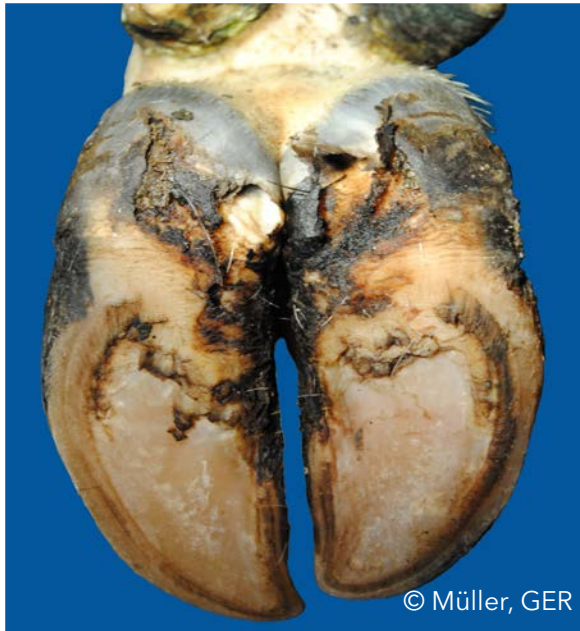Heel horn erosion (HHE)

Erosion of the bulbs, in severe cases typically V-shaped, possibly extending to the corium

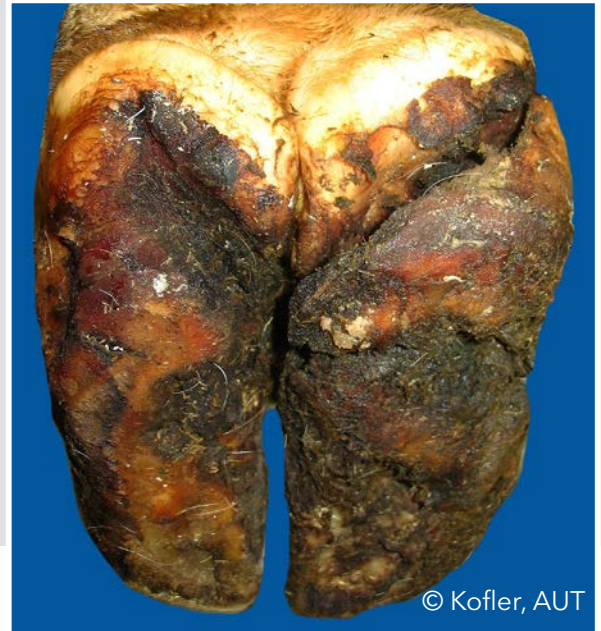

Heel horn erosion (HHE)

Erosion of the bulbs, in severe cases typically V-shaped, possibly extending to the corium



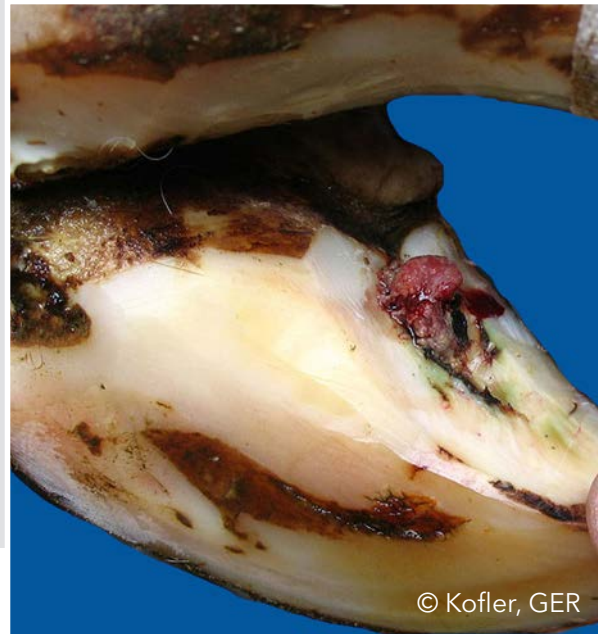
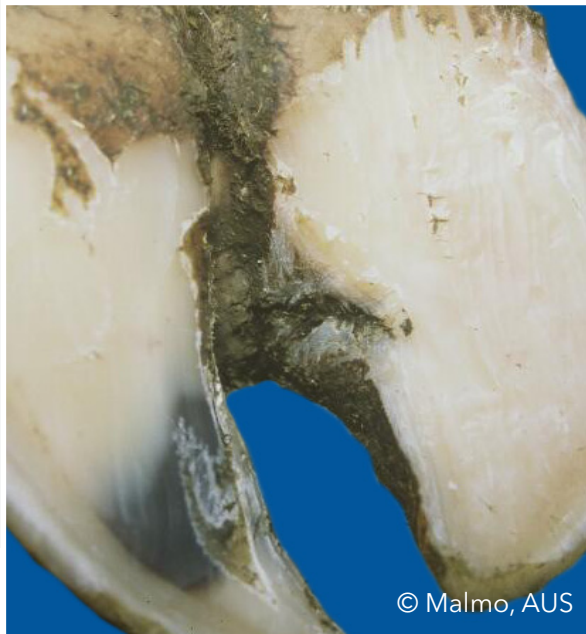© Müller, GER



© Kofler, AUT

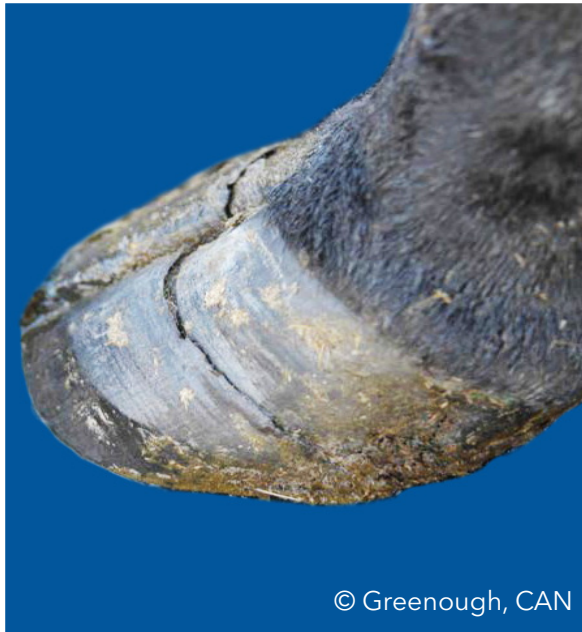Axial horn fissure (HFA)

Vertical (longitudinal) crack in the inner claw wall

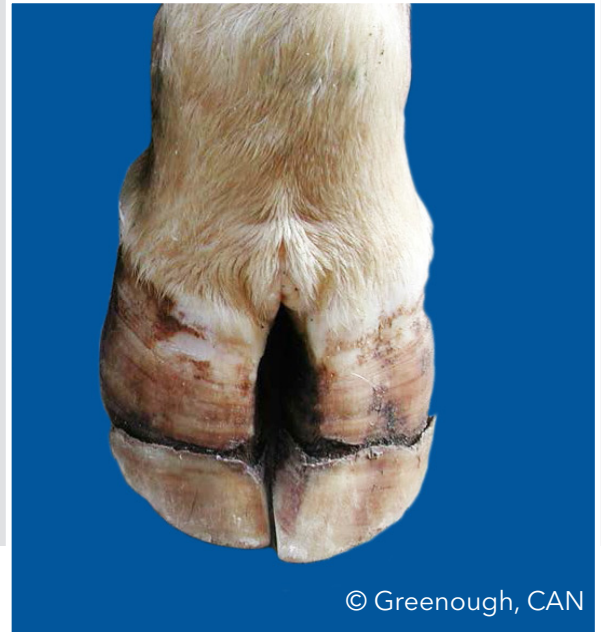


Horizontal horn fissure (HFH)

Horizontal crack in the claw wall



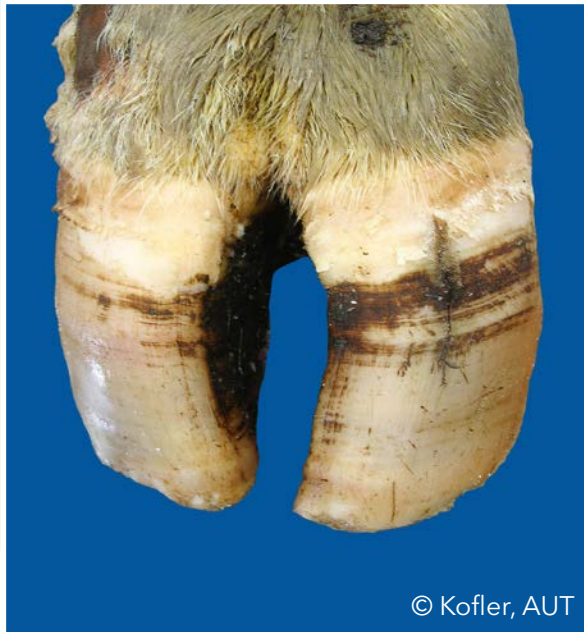© Greenough, CAN



© Greenough, CAN

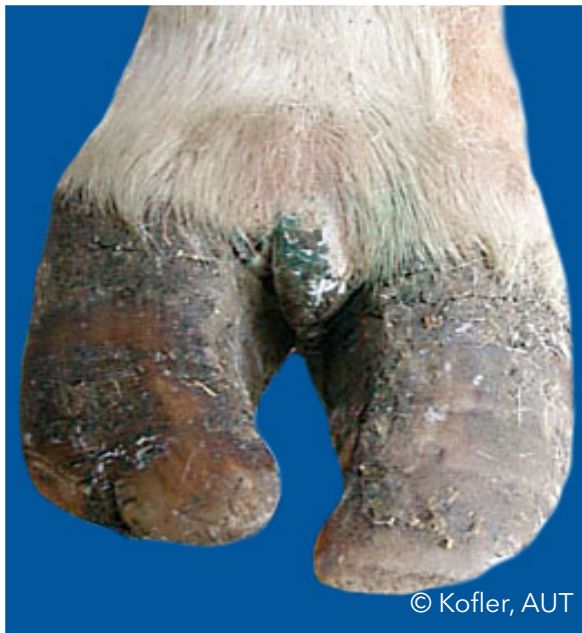Vertical horn fissure (HFV)

Vertical (longitudinal) crack in the outer or dorsal claw wall

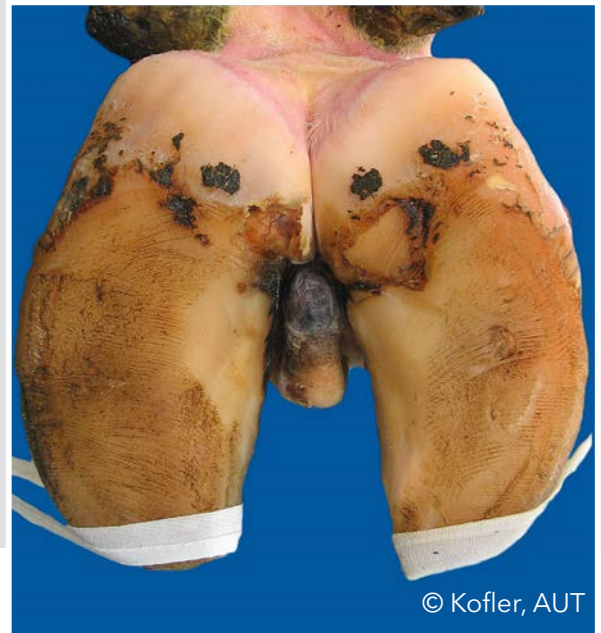


Interdigital hyperplasia (IH)

Interdigital growth of fibrous tissue



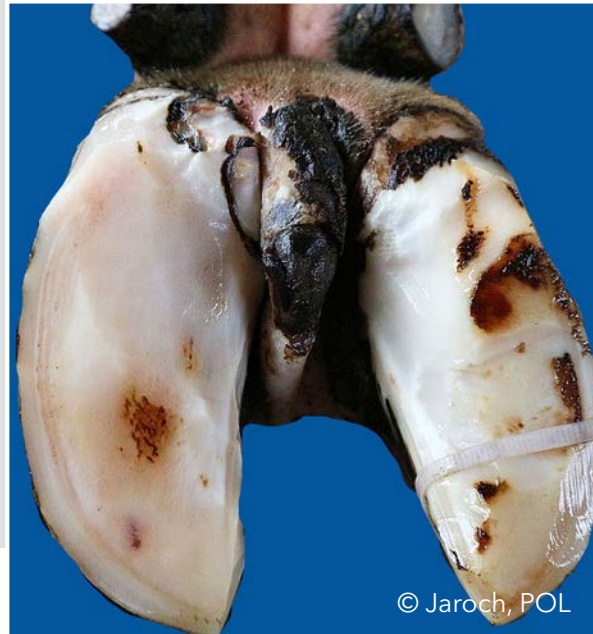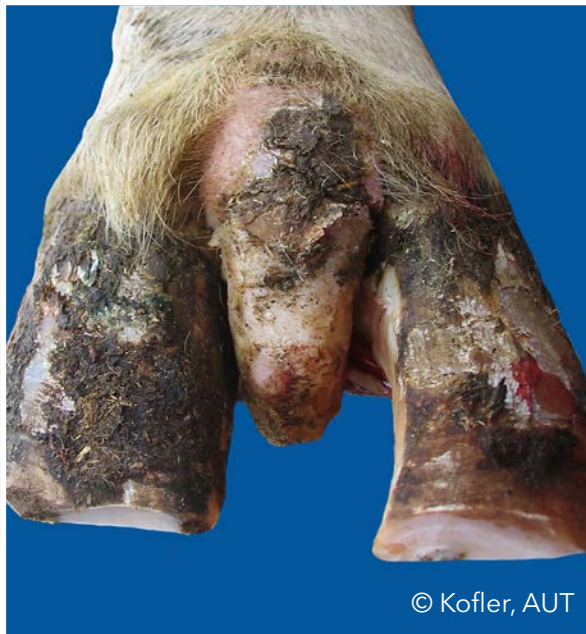© Kofler, AUT



© Kofler, AUT

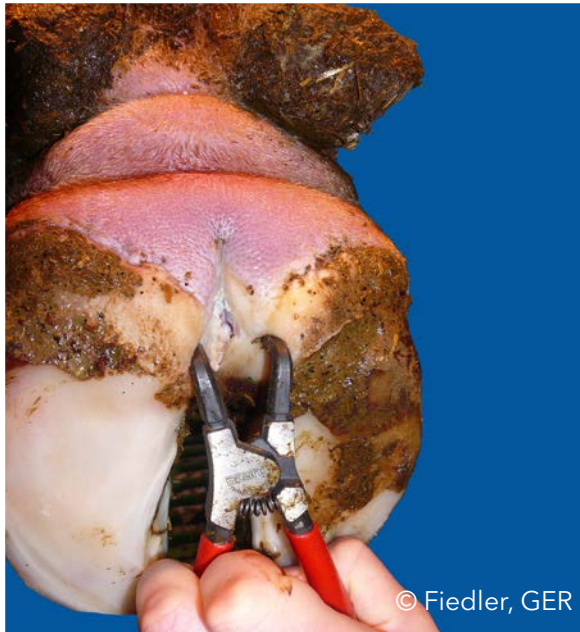
Interdigital hyperplasia (IH)

Interdigital growth of fibrous tissue

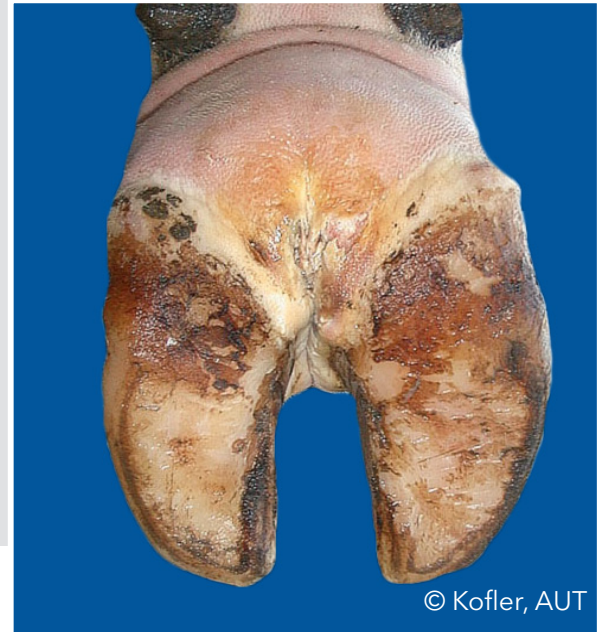

Interdigital phlegmon (IP)

Symmetric painful swelling of the foot commonly accompanied with odorous smell with sudden onset of lameness



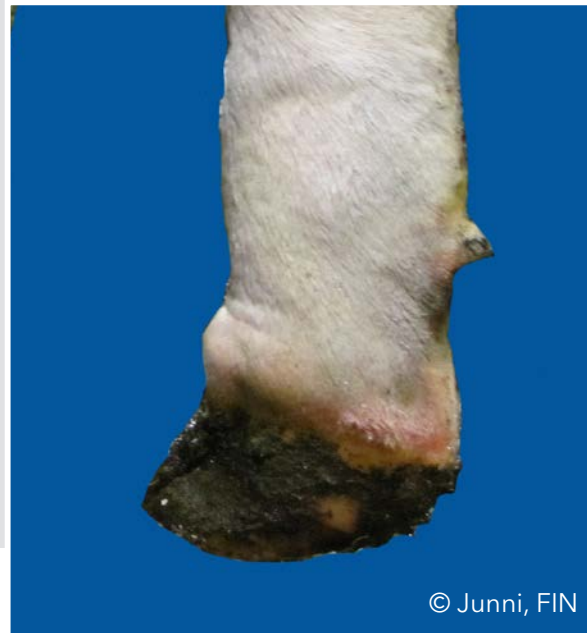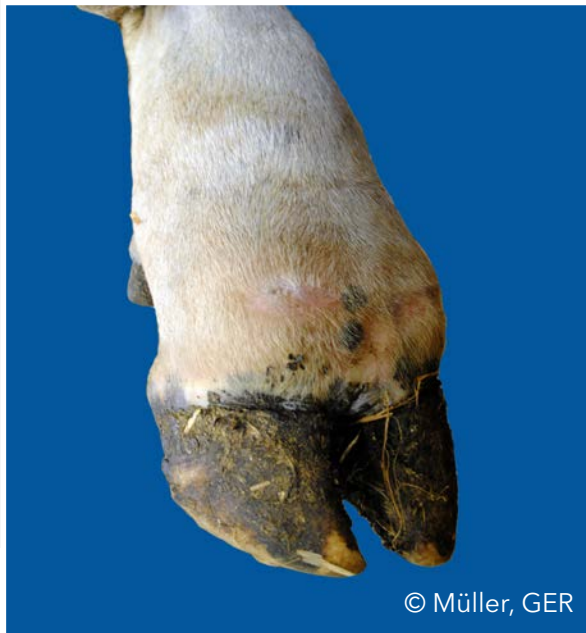© Fiedler, GER



© Kofler, AUT

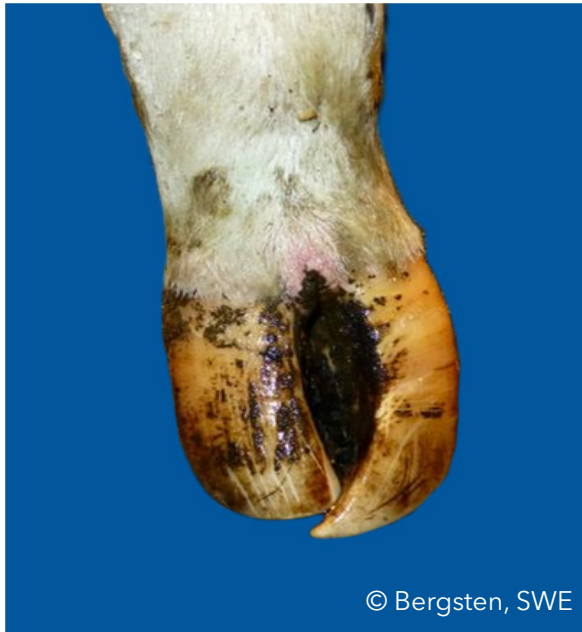Interdigital phlegmon (IP)

Symmetric painful swelling of the foot commonly accompanied with odorous smell with sudden onset of lameness

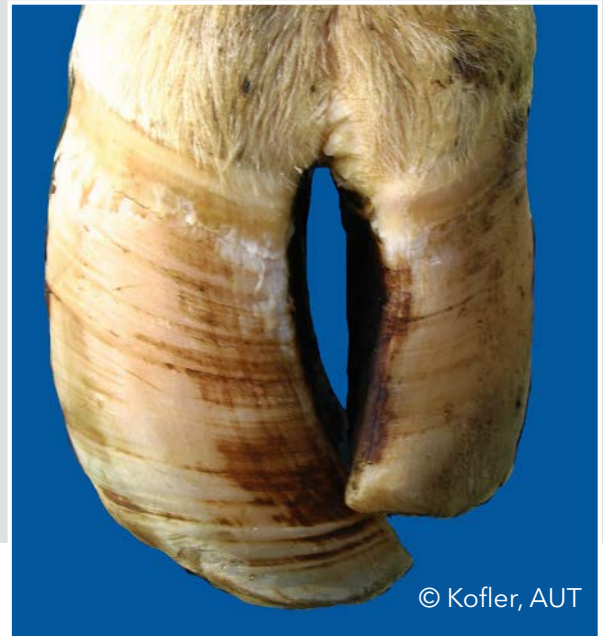

Scissor claws (SC)

Tip of toes crossing each other



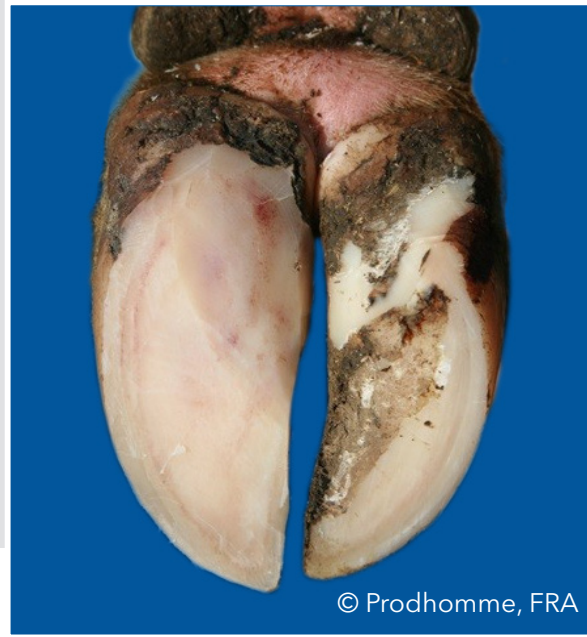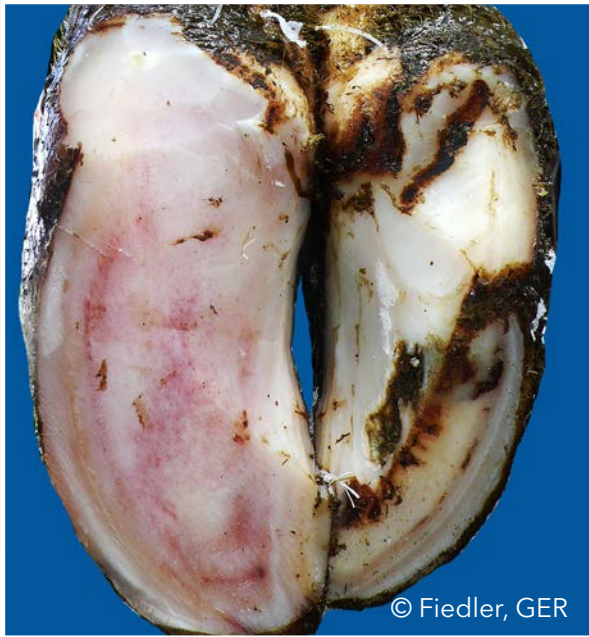© Bergsten, SWE



© Kofler, AUT

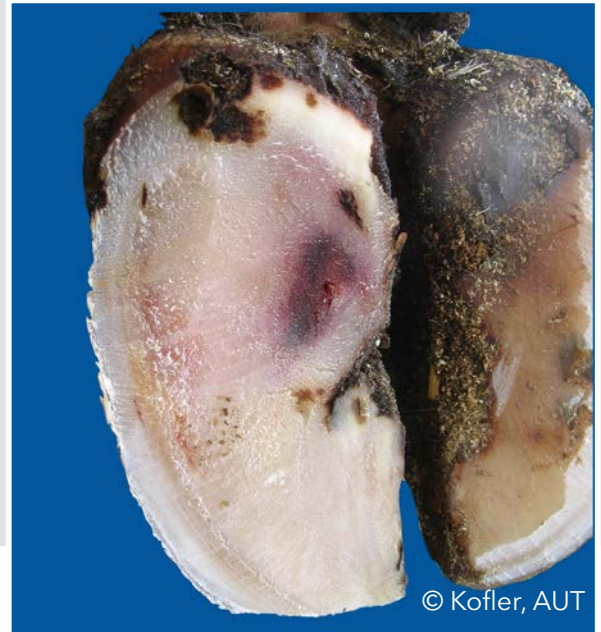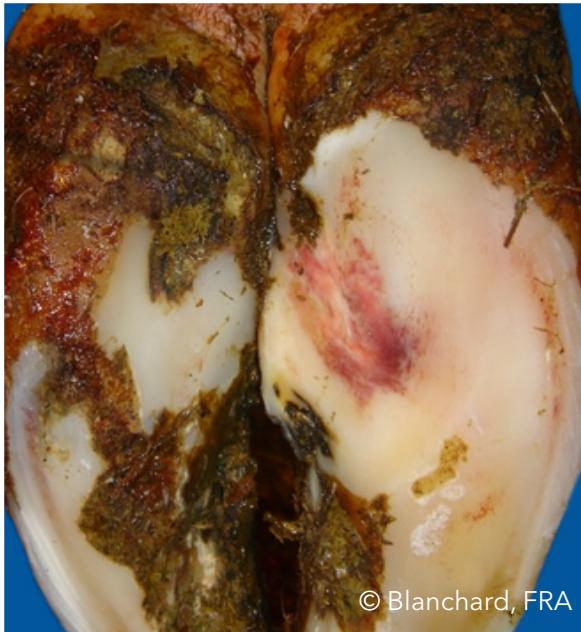Sole hemorrhage diffused (SHD)

Diffused light red to yellowish discoloration



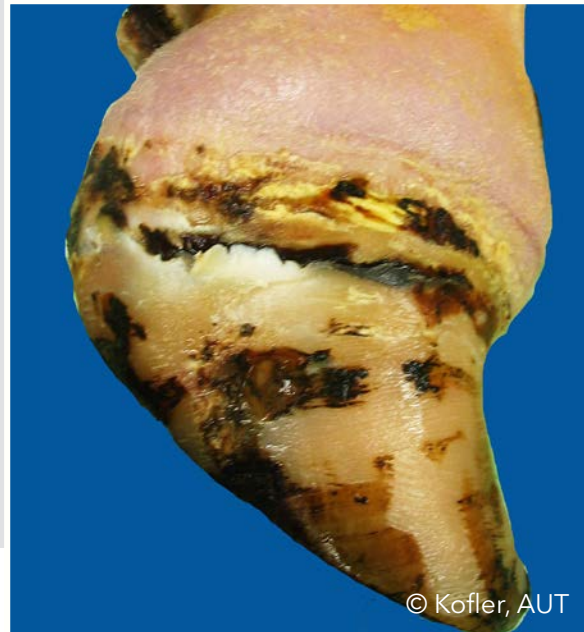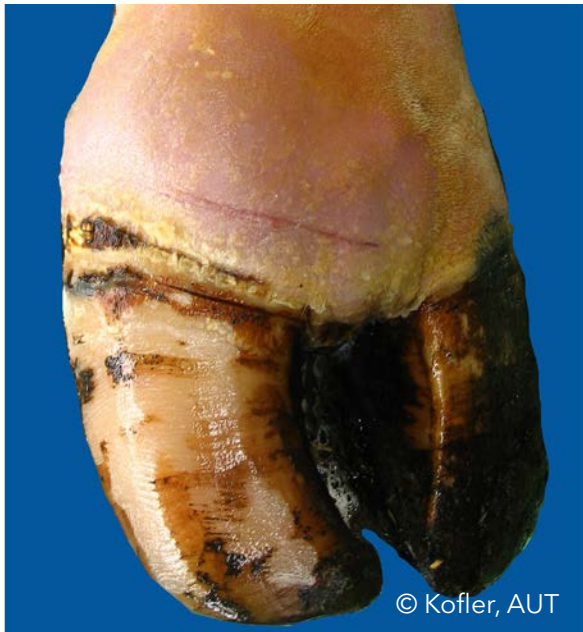Sole hemorrhage circumscribed (SHC)

Clear differentiation between discolored and normal colored horn



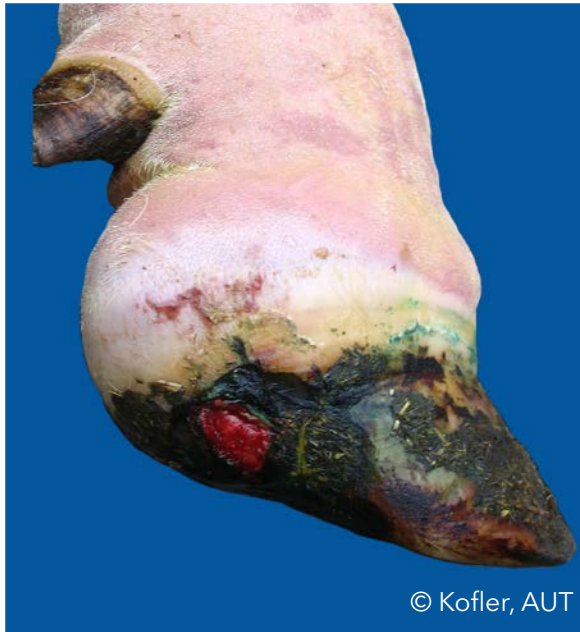Swelling of coronet and/or bulb (SW)

Uni- or bilateral swelling of tissue above horn capsule, which may be caused by different conditions

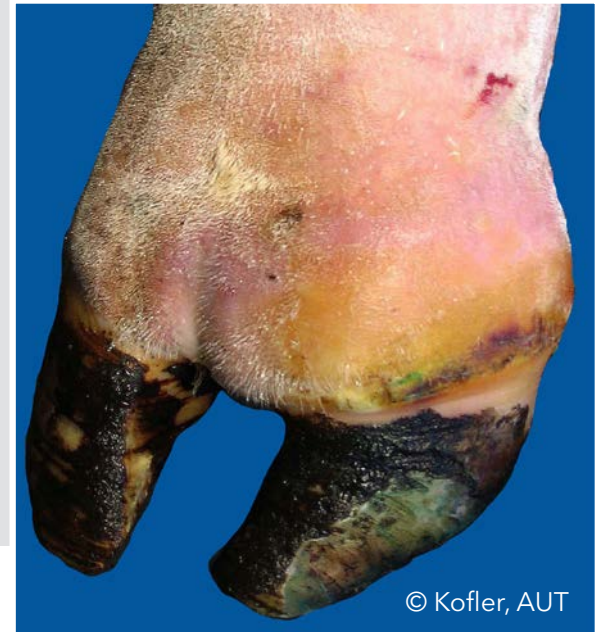

Swelling of coronet and/or bulb (SW)

Uni- or bilateral swelling of tissue above horn capsule, which may be caused by different conditions



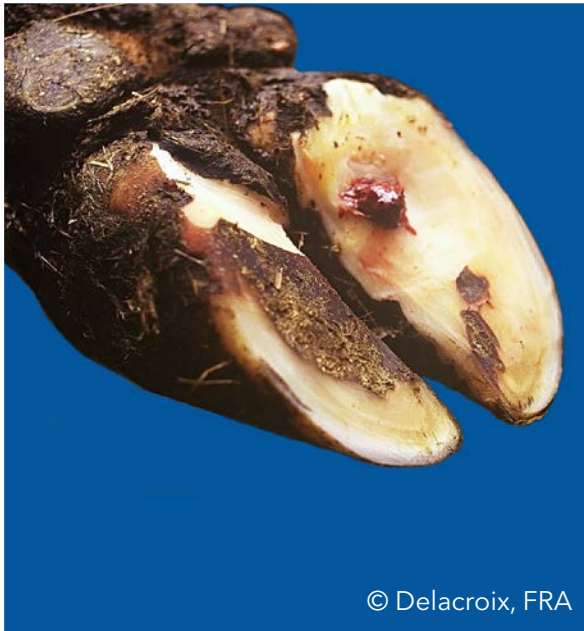
© Kofler, AUT



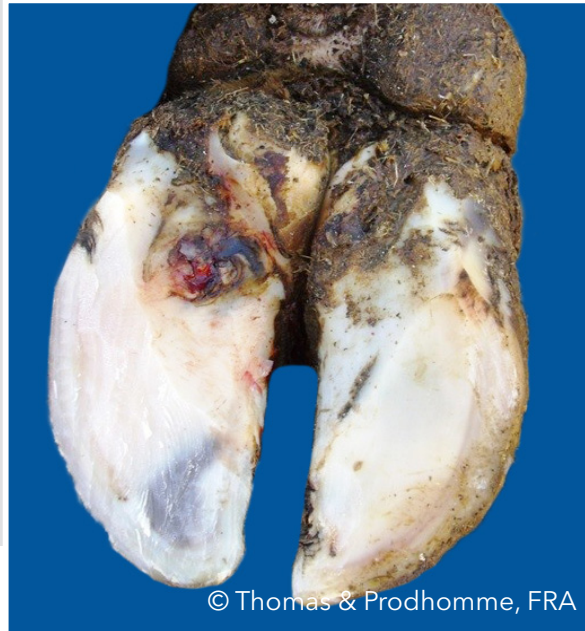
© Kofler, AUT

Sole ulcer (SU)

Penetration through the sole horn exposing fresh or necrotic corium



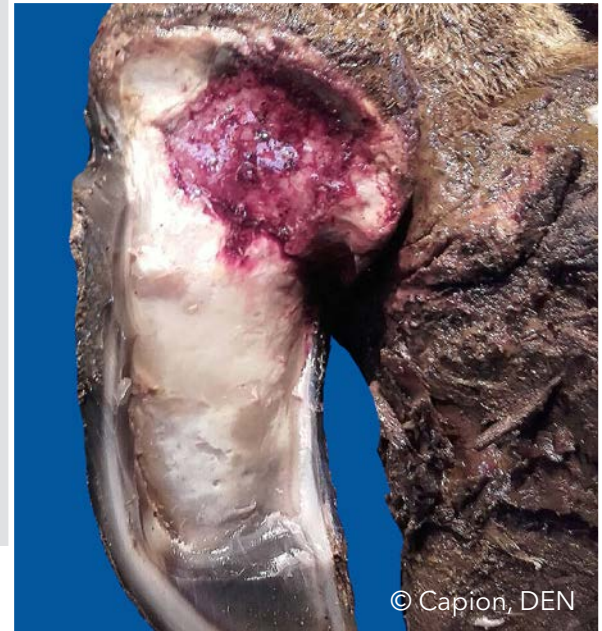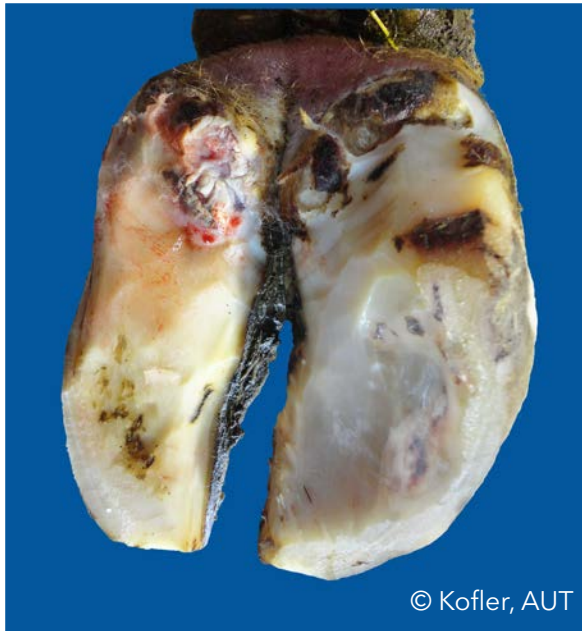
© Delacroix, FRA



© Thomas & Prodhomme, FRA

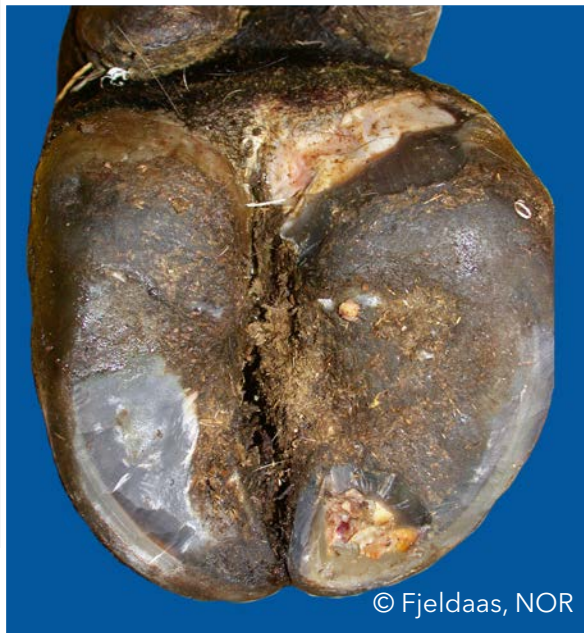Bulb ulcer (BU)

Ulcer located on the bulb

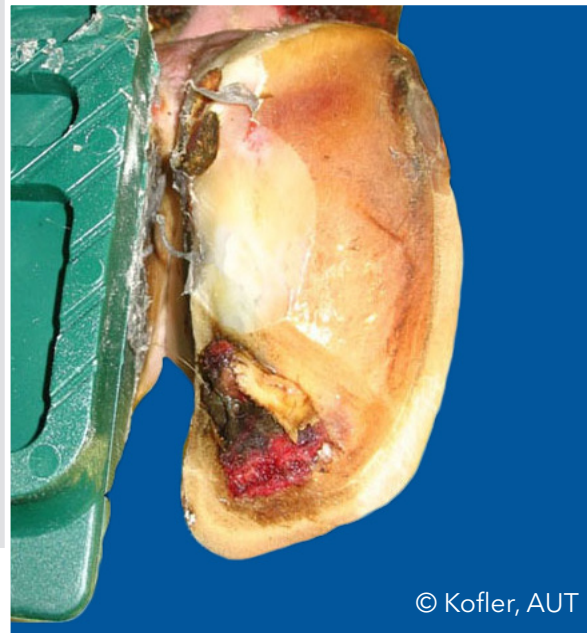

Toe ulcer (TU)

Ulcer located at the toe



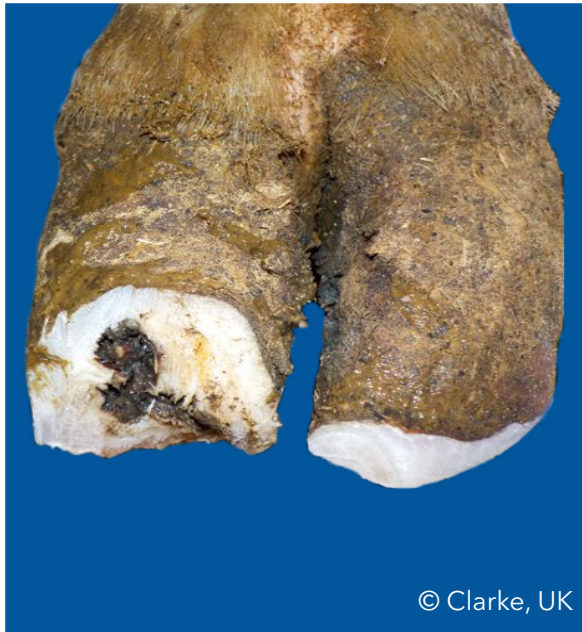© Fjeldaas, NOR



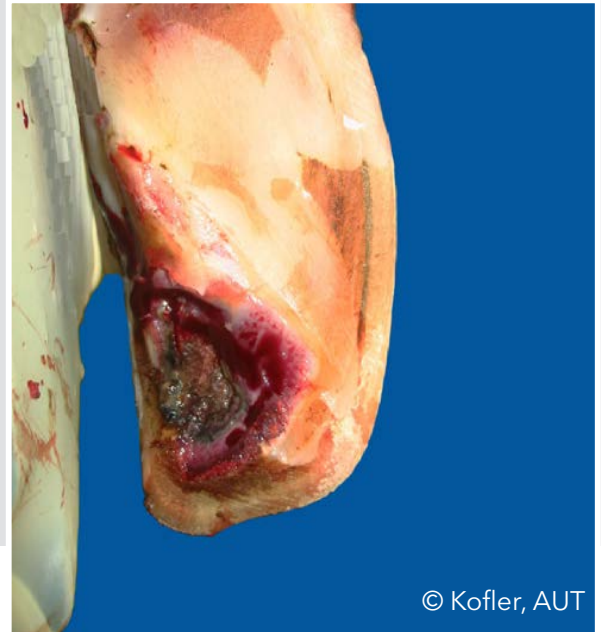© Kofler, AUT

Toe necrosis (TN)

Necrosis of the tip of the toe with involvement of bone tissue



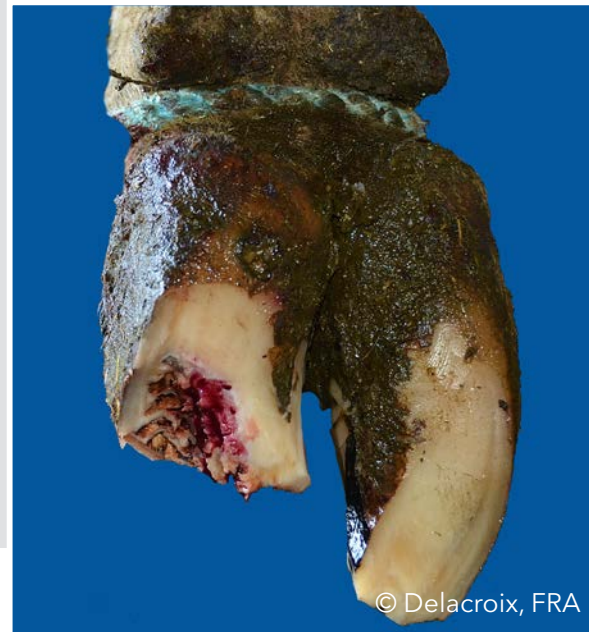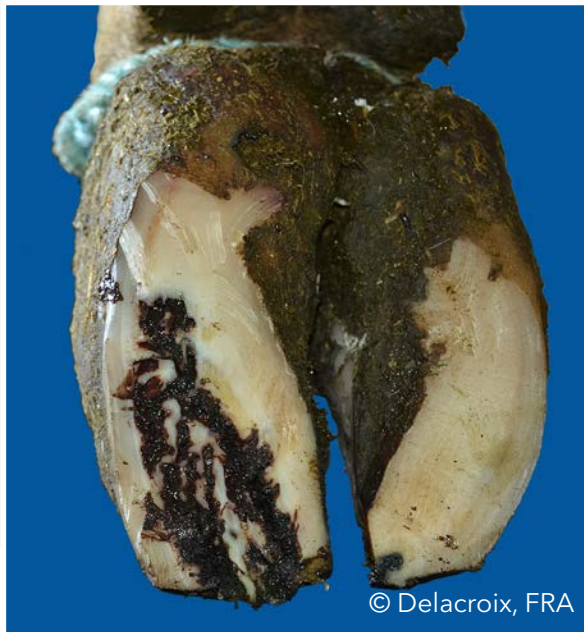© Clarke, UK



© Kofler, AUT

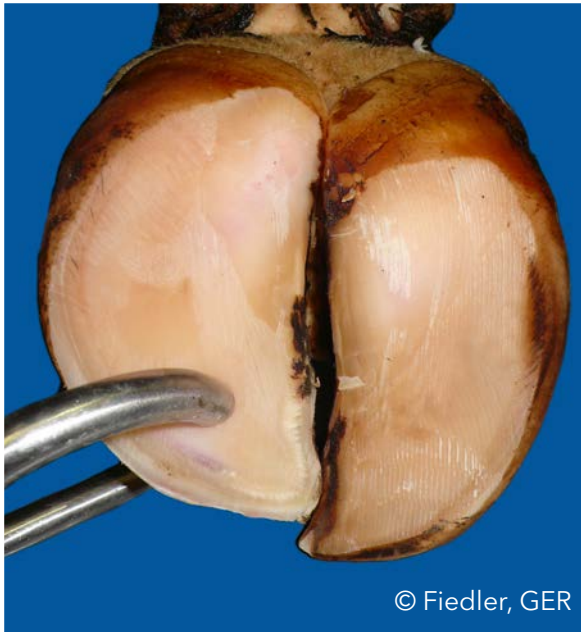
Toe necrosis (TN)

Necrosis of the tip of the toe with involvement of bone tissue

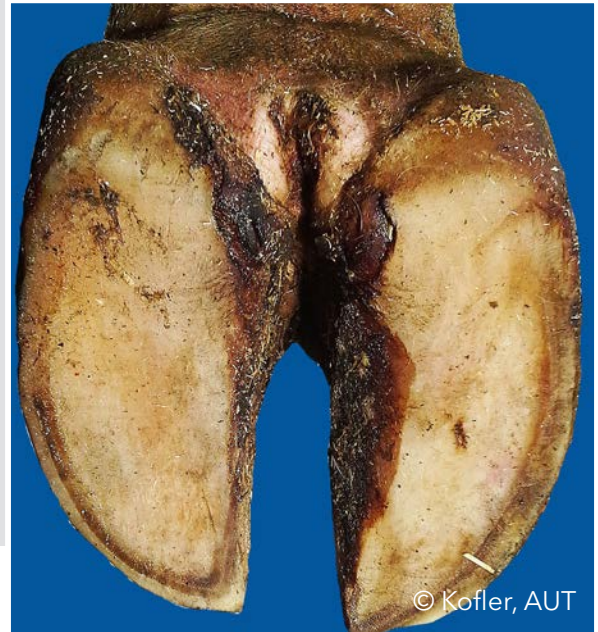

Thin sole (TS)

Sole horn yields (feels spongy) when finger pressure is applied



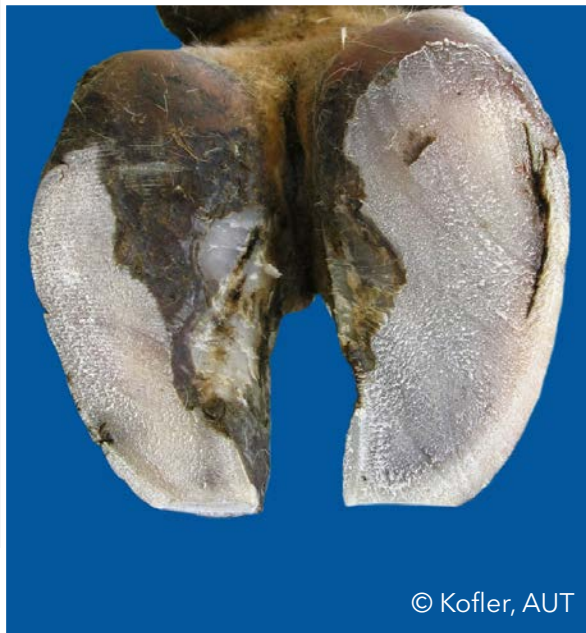© Fiedler, GER



© Kofler, AUT

White line fissure (WLF)

Separation of the white line which remains after balancing both soles



© Kofler, AUT



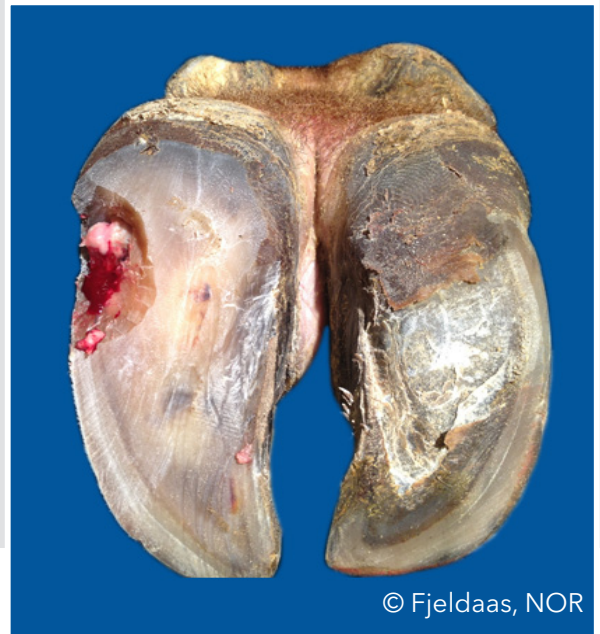
© Nielsen, DK

White line abscess (WLA)

Necro-purulent inflammation of the corium



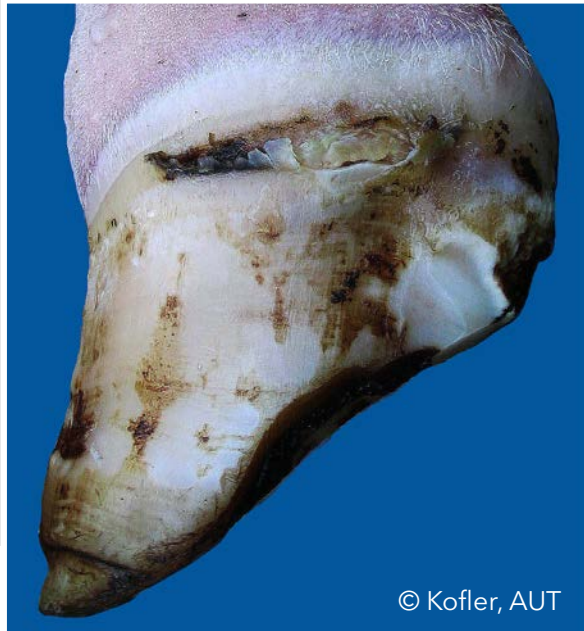© Kofler, AUT



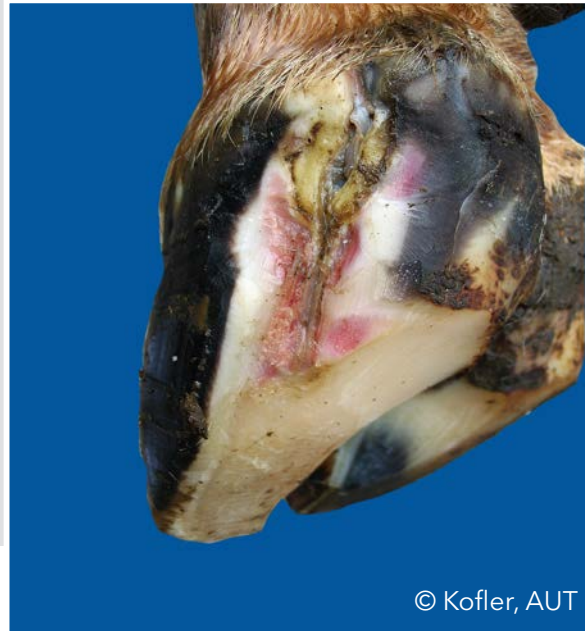© Fjeldaas, NOR

White line abscess (WLA)

Necro-purulent inflammation of the corium



© Kofler, AUT



© Kofler, AUT

List of Pictures

Bergsten, Christer (SWE): DS P19a; HFV P25b; SC P30a;

Blanchard, Joël (FRA): SHD P31b;

Capion, Nynne (DK): AC P12b; BU P36b;

Christen, Anne-Marie (CAN): DD P16a;

Clarke, Jonathan (UK): HHE P21b; TN P38a;

Daniel, Victor (CAN): Trimming P8;

Delacroix, Marc (FRA): SU P35a; TN P39a,b;

Greenough, Paul (CAN): HFH P24a,b;

Hausegger, Otto (AUT): Cover picture;

Fiedler, Andrea (GER): Trimming P45; AC P12a; CD P13a; DD P17a; ID 18b; DS 20b; IP P28a; SHD P31a; TS P40a;

Fjeldaas, Terje (NOR): DS P20a; TU P37a; WLA P42b;

Jaroch (POL): IH P27b;

Junni, Reijo (FIN): IP P29b;



List of Pictures

Knappe-Poindecker, Maren (NOR): ID P18a;

Kofler, Johann (AUT): CC P14a,b; DD P15b; DD 17b; DS P19b; HHE P22b; HFA 23b; HFV P25a; IH P26a,b; IH P27a; IP P28b; SC P30b; SHC P32b; SW P34a,b; BU P36a; TU P37b; TN P38b; TS P40b; WLF P41a; WLA P42a; WLA P43a,b;

Malmö, Jakob (AUS): HFA P23a;

Müller, Kerstin (GER): DD P15a; HHE P21a; HHE P22a; IP P29a;

Nielsen, Pia (DK): Trimming P5; WLF P41b;

Pesenhofer, Robert (AUT): Trimming P3;

Prodhomme, Jean (FRA): SHC P32a; SU P35b;

Thomas, Gilles (FRA): CD P13b; DD P16b; SU P35b;



© Fiedler, GER



